

**RADIATED SEMIOTICS OF BREAST PATHOLOGIES IN WOMEN
DEPENDING ON THE THYROID STATUS**

**Mardieva G.M.¹, Shukurova L.B.², Urinboeva D.S.³,
Giyasova N.K.⁴, Ahmedov Y.R.⁵ (Republic of Uzbekistan)
Email: Mardieva514@scientifictext.ru**

¹*Mardieva Gulshad Mamatmurodovna - Associate Professor;*

²*Shukurova Laziza Borisovna - Resident of the magistracy;*

³*Urinboeva Dilafruz Sunatilloevna - Resident of the magistracy;*

⁴*Giyasova Nigora Kobilovna - Assistant*

DEPARTMENT OF GENERAL SURGERY, RADIOLOGY AND THERAPY;

⁵*Ahmedov Yaqub Amandullaevich - Associate Professor,*

DEPARTMENT OF MEDICAL RADIOLOGY,

FACULTY OF POSTGRADUATE EDUCATION,

SAMARKAND STATE MEDICAL INSTITUTE,

SAMARKAND, REPUBLIC OF UZBEKISTAN

Abstract: analyzed the results of an X-ray diffraction study of 200 women with pathologies of the mammary glands with an assessment of thyroid status. In the examined women, thyroid hypofunction was noted in a slightly prevailing percentage of observations, confirmed by radiometry and laboratory data. With hypothyroidism, an increase in the number of observations of fibroadenomas and diffuse fibrotic mastopathies, characterized by pronounced processes of fibrosis and a violation of the regression of the glandular tissue, is determined. The opposite situation is observed in the incidence of breast cysts and variants of the normal structure of tissues, the number of such observations in patients with hypothyroidism was significantly less than in patients without hypothyroidism. In women with hypothyroidism and without hypothyroidism, almost the same number of cases of breast cancer was diagnosed.

Keywords: mammary gland, mammography, sonography, hypothyroidism.

**ЛУЧЕВАЯ СЕМИОТИКА ПАТОЛОГИЙ МОЛОЧНОЙ ЖЕЛЕЗЫ У
ЖЕНЩИН В ЗАВИСИМОСТИ ОТ ТИРЕОИДНОГО СТАТУСА**

**Мардиева Г.М.¹, Шукурова Л.Б.², Уринбоева Д.С.³,
Гиясова Н.К.⁴, Ахмедов Я.А.⁵ (Республика Узбекистан)**

¹*Мардиева Гульшиод Маматмуродовна - доцент;*

²*Шукурова Лазиза Борисовна – резидент магистратуры;*

³*Уринбоева Дилафруз Сунатиллоевна - резидент магистратуры;*

⁴*Гиясова Нигора Кобиловна - ассистент;*

кафедра общей хирургии, лучевой диагностики и терапии;

⁵*Ахмедов Якуб Амандуллаевич – доцент;*

кафедра медицинской радиологии,

факультет последипломного образования,

Самаркандский государственный медицинский институт,

Аннотация: изучены результаты рентгеносонографического исследования 200 женщин с патологиями молочных желез с оценкой тиреоидного статуса. У обследованных женщин гипофункция щитовидной железы отмечалась в несколько преобладающем проценте наблюдений, подтвержденная радиометрией и лабораторными данными. При гипотиреозе определяется увеличение количества наблюдений фиброаденом и диффузных фиброзных мастопатий, характеризующихся выраженными процессами фиброобразования и нарушением регресса железистой ткани. Обратная ситуация наблюдается во встречаемости кист молочной железы и вариантах нормального строения тканей, количество таких наблюдений у пациенток с гипотиреозом было значительно меньше, чем у пациенток без гипотиреоза. У женщин с гипотиреозом и без гипотиреоза диагностировано почти одинаковое количество наблюдений рака молочной железы.

Ключевые слова: молочная железа, маммография, сонография, гипотиреоз.

Introduction. Breast diseases develop very often. An important role in the structure of mammological morbidity is played by a diverse diffuse benign pathology and breast cancer [1-5]. It is enough to note that cancer of this organ is the most frequently diagnosed malignant tumor in women. Diagnosis is based on the results of a clinical examination and special studies, which are crucial for identifying the early stages of the disease [12-18]. In recent years, radiation diagnostics has taken an honorable place in this complex. The main radiological technique is mammography. Modern digital technologies open up new possibilities in the diagnosis and differential diagnosis of breast diseases [6-11].

The aim of the study was to study the characteristics of radiation semiotics of breast diseases in patients depending on thyroid status.

Material and research methods. We analyzed the results of a radiation study of women with pathologies of the mammary glands examined in 2016-2018. in the oncology clinic of the city of Samarkand. The study was conducted on a BM-2BX-RAY MAMMOGRAPHY UNIT digital mammograph and an EDAN DUS 6 ultrasound machine. 200 women were examined (54% aged 45 years and older, 46% younger than 45 years old). To assess the functional state of the thyroid gland, radiometry was performed and laboratory data were analyzed for studies of thyroid stimulating hormone (TSH) and thyroxine (T4).

The results of the study. In 40 (control group) of 200 women examined, pathology was not detected, in the remaining patients (160), various changes in the structure of the mammary glands were detected (table 1). Diagnostic mammograms were performed for patients in whom, on the basis of clinical data, a breast lesion was suspected: palpable seals, discharge from the nipple, mastodynia, complications after prosthetics of the mammary gland [2-6]. The study was carried out in the position of the patient lying on his back, arms lowered along the torso. For ease of examination, each mammary gland was conditionally divided in two ways. On four quadrants: upper-outer, upper-inner, lower-outer and lower-inner, as

well as 12 sectors according to the principle of the clock face. Thus, each quadrant was divided into three sectors. All sections of the mammary glands were examined, starting from the border with soft tissues of the anterior chest wall and ending with the perigastric region. Ultrasound examination included a mandatory examination of the regions of regional lymph outflow.

Color doppler mapping was performed to evaluate total vascularization. During energy doppler mapping of the mammary glands, blood flow in the lateral and medial mammary arteries, intraparenchymal vessels of the gland, and also vessels in the tumor nodes were evaluated. For this, the maximum diameter and length of the visualization of the detected Dopplerographic signs of blood vessels and their number were determined.

To achieve the objectives in order to study the pathologies of the mammary glands depending on the thyroid state, a laboratory analysis of the content of thyroid hormones in the blood was performed in 120 patients, including women in the control group, as well as radionuclide research methods in 80 patients. We analyzed the laboratory data of the study of TSH and T4. Relatively normal TSH indices in the control group were 0.3-4.22 IU/ML, T4 indices were 66-181NMOL/L. Radionuclide diagnostics of the thyroid gland included radiometry and gamma topography of the thyroid gland. To assess the intra-thyroid stage of iodine metabolism, the test subjects were given an empty stomach with a solution of ¹³¹I sodium iodide with an activity of 100-150 kBq, depending on the weight of the patient. Approximately 30% of the dose of radioactive iodine taken orally is absorbed by the thyroid gland within 24 hours after ingestion. The degree of absorption of radioactive iodine by radiometry on the surface of the thyroid gland was determined 2, 4, 24 hours after radiopharmaceutical analysis. In women with breast pathologies, according to radiometry and laboratory tests, thyroid hypofunction was observed in a slightly prevailing percentage of observations (62.5%), euthyroid state was detected in 12.5%, hyperthyroid state - in 25% of women. It should be noted that the prevailing number of patients with hypothyroidism with gammatopography showed an uneven structure of the thyroid gland, which is very characteristic of thyroiditis.

Depending on the presence or absence of hypothyroidism, all examined patients were divided into two groups. The first group consisted of patients with a reduced functional state of the thyroid gland, that is, hypothyroidism. The second group included women without hypothyroidism, i.e. with hyperfunction of the thyroid gland and euthyroid state. Hypothyroidism is a disease characterized by a decrease in thyroid function, decreased hormone production, and often a decrease in its overall size and volume. Studying the mechanisms of the influence of hypothyroidism on the reproductive system, the functional state of the gonads and mammary glands can be explained by a decrease in metabolic processes in the body with this pathology. It should be noted that in the control group (40 women) hypothyroidism was observed in 40% of cases, without hyperthyroidism - in 60%.

Table 1. Distribution of examined patients depending on the presence of hypothyroidism

№	Breast pathology	With hypothyroidism		Nohypothyroidism	
		Abs.	%	Abs.	%
1.	Cancer	8	5	8	5
2.	Mastitis	4	2,5	4	2,5
3.	Fibroadenoma	14	8,8	4	2,5
4.	Adenosis	6	3,8	2	1,3
5.	Diffusefibroticmastopathy	45	28,1	15	9,4
6.	Fibrouscysticmastopathy	18	11,3	8	5
7.	Cyst	4	2,5	2	1,3
8.	Infiltrativemastopathy	2	1,3	1	0,6
9.	Other	7	4,4	8	5
	Total	108	68	52	32

When revealing a volumetric formation or another type of pathological process in the mammary gland, blood flow in this zone was necessarily evaluated in comparison with the unchanged surrounding tissues by the symmetrical portion of the contralateral mammary gland. The main task of radiation diagnostics is the detection of breast cancer, especially at the stage when it is not determined either by the patient during self-examination, or by a doctor during examination and palpation of the breast, i.e. non-palpable cancer. The diagnosis of breast cancer was established and confirmed by cytological and histological studies in 16 women, which amounted to 10% of the total number of examined individuals with pathologies. When mammography from surrounding tissues the tumor was characterized by increased density. The shape of the knot was different. In two patients, this was a circle or oval shape, with an additional protrusion in the form of a prominence extending from one side of it. Even more typical was the star-shaped figure noted in the remaining patients, formed by a dense central core of an irregular configuration, from which gradually narrowing cords stretched into the surrounding tissue. For the cancerous node, jagged or small-wavy outlines, changes in the structure of the surrounding tissue were characteristic [1,6]. During energy doppler mapping, the blood flow was determined according to a mixed type (Fig. 1). Ultrasound examination on sonograms of the tumor was defined as a focal formation with uneven outlines and a heterogeneous structure. In six patients, the echogenicity of the tumor was low, since the glandular elements prevailed, and in 10 patients, on the contrary, the echogenicity of the tumor was increased, due to the predominance of stroma. In a demonstration of microcalcifications, sonography is less sensitive.

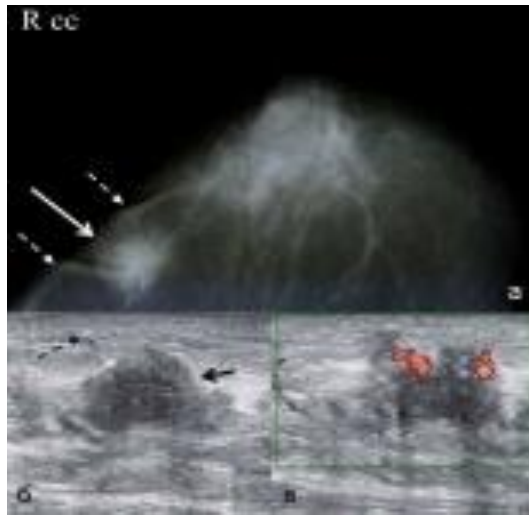


Fig. 1. Patient E., 63 years old. X-ray mammography of the right breast in a direct projection (a), ultrasound (b), energy Doppler mapping (c). Invasive ductal breast cancer. The formation of an irregular shape with heavy contours, an inhomogeneous structure (solid arrow) with thickening of the skin (dashed arrow) is determined. With energy Doppler mapping, blood flow is determined by a mixed type

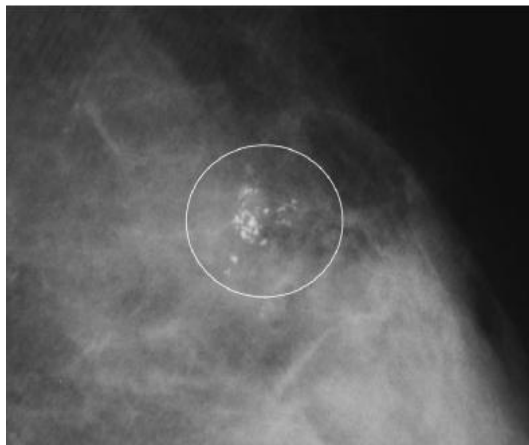


Fig. 2. X-ray mammography; enlarged fragment of the mammogram. Invasive ductal breast cancer. Grouped pleomorphic microcalcifications, mainly of a point shape, are determined, most of them against the background of compaction of soft tissue of the mammary gland of irregular shape with heavy contours

In women with hypothyroidism and without hypothyroidism, almost the same number of observations was diagnosed. Breast cancer was more often detected in the age group of 60-69 years of observation and was least likely to be detected in patients aged 30-39 years. Of the benign formations of the mammary gland, fibroadenoma is most often observed. Fibroadenoma was found in 18 women (11.2%). Fibroadenomas are the second most common in patients with hypothyroidism and without hypothyroidism. It gives on mammograms a rounded, oval or, less commonly, lobed shadow with smooth, sometimes slightly scalloped contours. The shadow of fibroadenoma is intense and uniform if it does not have

lime deposits. Calcifications were located both in the center and on the periphery of the node and looked like large lumps. Sonograms revealed heterogeneity of the fibroadenoma structure with its general reduced echogenicity. It should be noted that the sonograms made it possible to immediately distinguish the fibroadenoma from the cyst, which was not so easy to do by mammograms.

The dopplerographic study of vascularization of pathological tissues in the mammary gland was based on its qualitative assessment and comparison with unchanged areas of the mammary gland, without assessing the spectral characteristics of blood flow (Fig. 3). With energy Doppler mapping with fibroadenomas, peripheral blood flow was observed.

The number of fibroadenomas was slightly higher in patients with hypothyroidism than in patients without hypothyroidism - 14 (8.8%) cases and 4 (2.5%) cases, respectively. The most common pathological condition of breast tissue, regardless of the presence or absence of hypothyroidism, was diffuse mastopathy. Changes characteristic of diffuse fibrotic mastopathy were visualized in 60 women (37.5%). The fibrous form of mastopathy was expressed in the fact that the shadow of the glandular part became intense and almost uniform. Against this background, separate coarser strands stood out, sometimes lime deposits were visible along the milk ducts. In most cases, the X-ray picture of fibrotic mastopathy was characterized by the presence of multiple shadows of irregular shape with underlined contours against a dense relatively homogeneous stromal triangle. The ultrasound picture of the disease was characterized by the presence of a fibrous component in the stromal complex, which predominantly equally prevailed in volume over the fatty and glandular components. In patients with hypothyroidism, various forms of diffuse mastopathy were significantly more common than in patients without hypothyroidism.

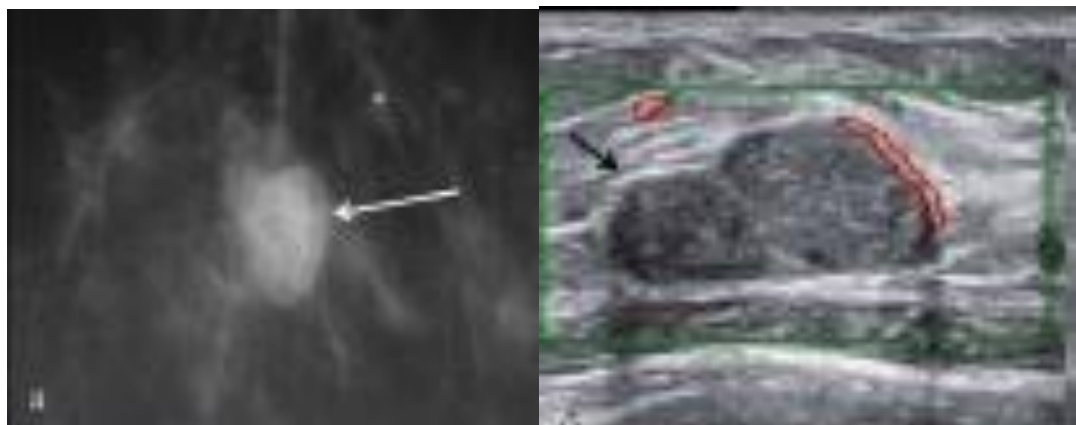


Fig. 3. Patient N., 66 years old. X-ray mammography; a fragment of a mammogram in a direct projection (a), an ultrasound study using energy Doppler mapping (b). Pericardial fibroadenoma. The formation of an oval shape with even clear contours, a moderately heterogeneous structure (arrow) is determined, peripheral blood flow is noted. Microcalcifications are detected in nearby tissues.

Fibrocystic mastopathy was visualized in 26 (16.3%) patients. Breast cysts were identified in 6 women (3.7%). Small cystic restructuring, as a rule, occurred in both mammary glands. Larger cysts appeared in the form of rounded and oval shadows of different sizes - from 0.5 to 3-4 cm with clear even arched contours. The multi-chamber cyst had polycyclic outlines. The shadow of the cyst was always uniform without lime deposits. The most demonstrative cyst was in sonograms. When the sensor applied pressure to the cyst, its shape changed.

Breast cysts are more common in patients without hypothyroidism - 4 (2.5%) cases, compared with patients with hypothyroidism - 2 (1.3%) cases. In patients with hypothyroidism, breast cysts were most often determined in the age group of 40-49 years. Among patients without hypothyroidism, breast cysts are most often identified in the age group of 50-59 years. Differential diagnosis of cysts and fibroadenomas required mandatory ultrasound of the mammary glands.

The information content of ultrasound decreased with fat involution (20%), due to weak ultrasound contrast between tumor and adipose tissue, as well as with pronounced cicatricial changes. The diagnosis of mastitis in 8 patients (5%) was carried out on the basis of clinical data, but sonography was a valuable auxiliary method. In the initial period of mastitis, the obscurity of the usual picture of the gland was determined. In the glandular part, echo-negative inclusions 0.3-0.5 cm in size appeared, often located in groups. It should be noted that the emerging rarefaction site against this background indicated the destruction and development of purulent mastitis. In 3 cases (1.9%), changes characteristic of infiltrative mastopathy were noted. Mixed forms of mastopathy caused a colorful x-ray picture: instead of a sharply defined shadow of the glandular triangle with trabeculae radially diverging from the base of the gland to the areola, a restructuring of the gland structure with multiple areas of darkening and enlightenment of various shapes and sizes, the so-called "lunar relief", was revealed. Features of the development of diffuse mastopathy have a significant impact both on the condition of patients and on the effectiveness of the diagnosis of breast cancer and other breast cancer diseases. Hypothyroidism should be attributed to risk factors for the development of diffuse mastopathy, in the first place, forms characterized by pronounced processes of fibrosis and impaired regression of the glandular tissue - adenosis, fibroadenomatosis and sclerosingadenosis. Thus, sonography is preferable in differentiating fibroadenomas from cysts, and less specific in detecting microcalcifications. The informational content of ultrasound decreased with fat involution, due to weak ultrasound contrast between tumor and adipose tissue, as well as with pronounced cicatricial changes. Dopplerographic signs were characterized by an envelope type of blood flow with a segmental intranasal vessel for fibroadenomas and a mixed type of blood flow in breast cancer. Diffuse fibrotic mastopathy is characterized by the presence of a fibrous component in the stromal complex, which equally prevailed in volume over the fatty and glandular components.

As can be seen, for patients diagnosed with hypothyroidism, in order to increase the effectiveness of the diagnosis of breast diseases, it is necessary to conduct a diagnostic complex consisting of x-ray mammography and ultrasound with energy

Doppler mapping. Our data suggest that changes in the hormone-producing function of the thyroid gland lead to a pronounced violation of the production of gonadotropic hormones, as a result of which various pathologies of the mammary gland and disturbances in the functioning of the woman's reproductive system may occur.

Findings. In women with breast pathologies, thyroid hypofunction was observed in a slightly prevailing percentage of cases. With hypothyroidism, an increase in the number of observations of fibroadenomas and diffuse fibrotic mastopathies, characterized by pronounced processes of fibrosis and a violation of the regression of the glandular tissue, is determined. The opposite situation is observed in the incidence of breast cysts and variants of the normal structure of tissues, the number of such observations in patients with hypothyroidism was significantly less than in patients without hypothyroidism. In women with hypothyroidism and without hypothyroidism, almost the same number of cases of breast cancer was diagnosed.

References / Список литературы

1. Абдураимов А.Б., Лесько К.А. Роль качественной эластографии в ультразвуковой диагностике мелких доброкачественных доплерографически аваскулярных образований молочной железы при гипотиреозе // Опухоли женской репродуктивной системы, 2014. № 4.
2. Бабажанов А.С. и др. Профилактика гипотиреоза в послеоперационном периоде у больных с многоузловым нетоксическим зобом // Проблемы биологии и медицины, 2017. № 2. С. 25.
3. Бабажанов А.С., Жониев С.Ш., Рахимов А.У. Анализ эффективности вариантов предоперационной подготовки и анестезии в лечении заболеваний щитовидной железы // Проблемы биологии и медицины, 2017. № 1. С. 58.
4. Даминов Ф.А. и др. Хирургическая тактика лечения диффузно-токсического зоба // Академический журнал Западной Сибири, 2013. Т. 9. № 1. С. 21-21.
5. Зайниев А.Ф., Юнусов О.Т., Суярова З.С. Результаты хирургического лечения больных узловым зобом // Вестник науки и образования, 2017. Т. 1. № 6 (30).
6. Жониев С.Ш., Рахимов А.У., Бабажанов А.С. Значение биохимических показателей при предоперационной подготовке больных узловым зобом // Science and world, 2013. С. 136.
7. Курбанов Д.Д., Амонов И.И. Новый подход к лечению анемии беременных при заболеваниях щитовидной железы с учетом концентрации микроэлементов в организме // Проблемы биологии и медицины (Узбекистан), 2003. № 11. С. 28.
8. Терновой С.К., Абдураимов А.Б., Лесько К.А. Лучевая диагностика рака молочной железы у женщин с гипотиреозом // Опухоли женской репродуктивной системы, 2013. № 3-4.

9. *Хамдамов И.Б.* Прогестагены и перспективы использования комбинированных гормональных контрацептивов // Проблемы биологии и медицины, 2012. Т. 1. С. 179.
10. *Юсупова А.А., Курбанова Н.С.* Структурное и функциональное состояние щитовидной железы у подростков в регионе с йодовой недостаточностью // Проблемы биологии и медицины, 2012. Т. 1. С. 144.
11. *Kasimov S. et al.* Haemosorption in complex management of hepatargia // The International Journal of Artificial Organs, 2013. Т. 36. № 8.
12. *Mardieva G.M., Shodiev F.G., Shukurova L.B.* Ray visualization of breast pathology in women depending on thyroid status. // problems of biology and medicin, 2018. № 2 (100). P. 51-56.
13. *Slepov V.P. et al.* Use of ethonium in the combined treatment of suppurative and inflammatory diseases in children // Klinicheskaiia khirurgiia, 1981. № 6. С. 78.
14. *Sultanbaevich B.A. et al.* The states of the thyroid residue in the postoperative period in patients with multinodal nontoxic goiter // European science review, 2018. № 9-10-2.
15. *Yusupov S.A.* Long-term results of surgical treatment of thyroid nodules// i experimentally! Medicine, 2017. № 1. P.43-46
16. *Mardieva. G.M., Narzikulov Sh., Babayarov A., Yanova E.U., Fayzieva D.A.* Peculiarities of x-ray semiotics in early age children with pneumonia.// «European science review». Vienna, 2018.№ 11-12. Т. 2. P. 103-105.
17. *Turdumatov Zh.A., Mardieva G.M., Fayzieva D.A., Yanova E.U.* Improving the radiological diagnosis of chronic obstructive pulmonary disease. / International scientific-practical Internet conference "Tenden to prospect science i develop in the minds of globalization". Ukraine, 2019. № 44. P. 538-541.
18. *Yusupov S. A. et al.* Отдаленные результаты оперативного лечения узловых образований щитовидной железы // Здобутки клінічної і експериментальної медицини, 2017. № 1.
- 19.